

Prediction of Cement Volume for Vertebroplasty Based on Imaging and Biomechanical Results

Gye-Rae Tack, Seung-Yong Lee

Department of Biomedical Engineering Konkuk University, Seoul 143-701, Korea

Sung-Jae Lee*, Bong-Jae Jun, Do-Hyung Lim

Department of Biomedical Engineering, Inje University, Kyungnam 621-749, Korea

Jung-Woog Shin, Jeong-Koo Kim, Kyu-Chul Shin

Department of Orthopedics, Konkuk University, Seoul 143-701, Korea

Control of bone cement volume (PMMA) may be critical for preventing complications in vertebroplasty, the percutaneous injection of PMMA into vertebra. The purpose of this study was to predict the optimal volume of PMMA injection based on CT images. For this, correlation between PMMA volume and textural features of CT images was examined before and after surgery to evaluate the appropriate PMMA amount. The gray level run length analysis was used to determine the textural features of the trabecular bone. Estimation of PMMA volume was done using 3D visualization with semi-automatic segmentation on postoperative CT images. Then, finite element (FE) models were constructed based on the CT image data of patients and PMMA volume. Appropriate material properties for the trabecular bone were assigned by converting BMD to elastic modulus. Structural reinforcement due to the changes in PMMA volume and BMD was assessed in terms of axial displacement of the superior endplate. A strong correlation was found between the injected PMMA volume and the area of the intertrabecular space and that of trabecular bone calculated from the CT images ($r=0.90$ and -0.90 , respectively). FE results suggested that vertebroplasty could effectively reinforce the osteoporotic vertebra regardless of BMD or PMMA volume. Effectiveness of additional PMMA injection tended to decrease. For patients with BMD well lower than 50mg/ml, injection of up to 30% volume of the vertebral body is recommended. However, less than 30% is recommended otherwise to avoid any complications from excessive PMMA because the strength has already reached the normal level.

Key Words : Vertebroplasty, Bone Cement, Image Analysis, Biomechanics, FEM

Nomenclature

E	: Elastic modulus
p	: Significant probability
r	: Correlation coefficient
R ²	: Coefficient of determination
QCT	: The level of BMD (Bone Mineral Density) by quantitative computed tomography measurement

* Corresponding Author,
E-mail : sjl@bme.inje.ac.kr
TEL : +82-55-320-3452 ; **FAX :** +82-55-337-1303
 Department of Biomedical Engineering Inje University,
 Obang-Dong, Kimhae, Kyungnam 621-749, Korea.

1. Introduction

Percutaneous vertebroplasty is an effective new surgical procedure that was introduced to treat hemangiomas in the spine in late 1980's in France (Deramond, 1998). It is still regarded as a relatively new surgical procedure considering the fact that it was not introduced in the United States until 1994. It includes injection of polymethylmethacrylate (PMMA) into the cancellous bone of the vertebral body using special gauge needles. Recent studies have shown that it is a minimally

invasive and safe procedure that can reinforce the structural integrity of the weakened vertebrae with immediate pain relief. It is also known to be very effective for the patients suffering from osteoporotic fractures or selected vertebral column neoplasms. However, there exist several limitations: They include the inability to restore the original height of the vertebrae, lack of clinical reports on its use on younger people, insufficient data on long-term effects, and thermal damage by the polymerization of bone cement after injection (Deramond, 1999). It is also reported that disproportionate volume of PMMA injection is one of the most common causes of complications (Martin 1999, Barr 2000). The known disadvantages of PMMA such as thermal necrosis of surrounding tissue, inability to remodel and integrate with bone, and toxicity of monomers can make it more prone to complications if extravagation occurs. On the other hand, insufficient injection of PMMA would be possibly insufficient to properly reinforce the vertebra against the risk of fracture. Since the degree of the osteoporosis can influence the porosity of the cancellous bone in the vertebral body, the injection volume can be different from patient to patient. Therefore, clinical success of vertebroplasty can be dependent on the PMMA injection volume and bone mineral density (BMD) for a given patient with osteoporosis.

Estimation of PMMA volume requirement for a given patient can be done with image analysis on the preoperative CT images. The texture analysis can characterize tissues to determine changes in functional characteristics of organs at the onset of disease (Mir, 1995). It is reported that texture analysis was useful for the assessment of the fracture risk especially in elderly women who are very vulnerable to osteoporosis (Ito, 1995). 3D visualization can be applied in several medical applications to clarify patient anatomy or to plan surgical operations. 3D visualization with semi-automatic segmentation can be applied to postoperative CT images to estimate the amount of PMMA injection volume and to compare that with the actual amount of PMMA during vertebroplasty.

The methods of finite element (FE) analysis

are frequently used in orthopedic biomechanics to evaluate the structural integrity of a given anatomic region or the efficacy of a surgical construct. Clinically relevant finite element models can be constructed for a specific patient based on his/her CT image data. They contain BMD data of patient, volume and location of PMMA that is injected, and morphologic data of patient's vertebra. With appropriate loading and boundary conditions, FE models can be simulated to evaluate the structural reinforcement that is achieved by PMMA injection.

In this study, the appropriate amount of PMMA injection in vertebroplasty was investigated for different levels of BMD of the patients based on image and biomechanical analyses. For this, the following hypotheses were made: 1) a relationship could be drawn between the amount of PMMA injection and textural features of the trabecular bone in preoperative CT images, 2) an amount of PMMA injection could be estimated based on 3D reconstruction of postoperative CT images, and 3) the degree of structural reinforcement in the osteoporotic vertebrae could be assessed with respect to changes in the amount of PMMA injection and the level of BMD of patients, and finally 4) the optimal PMMA volume could be predicted based on the imaging and biomechanical results. The gray level run length analysis was used to extract textural features of the trabecular bone. The correlation between PMMA volume and textural features of patient's CT images was examined and an appropriate PMMA amount for the vertebroplasty was suggested. The amount of PMMA volume injection was estimated based on 3D reconstruction of postoperative CT images. The degree of structural reinforcement in the osteoporotic vertebrae was investigated using FE models that were constructed based on the image data of the patients. Further, the efficacy of the vertebroplasty was demonstrated and the optimal level of PMMA volume was suggested for a patient based on the biomechanical results.

2. Materials and Methods

Eight female patients (age, 57–78 years) underwent percutaneous injection of bone cement with fluoroscopic guidance. Patient data are included in Table 1. A total of 14 vertebrae with osteoporosis were involved. Xpeed Unit (Toshiba, 120kvp, 170 mA, 2.7sec) was used for CT measurement (512×512 , 1-mm thickness). Vertebrae were scanned before and after the percutaneous vertebroplasty. Fig. 1 shows typical pre- and post-operative CT images. The radiopaque region of the image is the actual PMMA injected area.

From various pools of texture analysis methods such as the spatial gray level dependence method,

Table 1 Patient and surgical data

Patient No.	BMD (mg/ml)	Level of Vertebral Body	Group No.	Volumetric % of Injected PMMA
1	11.2	T11*	1	15
2	20.4	T8,L1*	2	30
3	30.8	L1*	3	20
4	49.1	L1*	4	10
5	20.5	T7,11,12	2	28
6	18.1	T7,8,10,11	2	27
7	9.7	L1	1	9
8	36	L2	3	22

*: indicate the levels and the patients selected for the biomechanical analysis

the gray level run length method, and the gray level difference method, the gray level run length analysis was used to determine the textural features of the trabecular bone in this study. For a digital image, a run is defined as a sequence of consecutive pixels with an identical gray level oriented along a specified direction. The run length means the length of the sequence. In the run length analysis, two indices were used as textural parameters to represent the textural features: the area of intertrabecular space and the area of the trabecular bone. In this study, we followed the procedure suggested by Ito et al. to do texture analysis (Ito, 1995). CT images (512×512 , 12 bits) of patients before percutaneous vertebroplasty were converted into binary images to obtain textural features of each image. The CT values of each image were converted in a linear fashion into 256 gray levels. The rolling ball subtraction algorithm was used to remove the smooth, continuous background of the gray level image before making a binary image (Sternberg, 1983). After removal of background, the images were converted into binary images with two gray levels (0 and 1). The same threshold was used for all series and was applied to the ROI (64×64) within an image. The ROI was selected manually within the trabecular bone. The bound of the run length was set to 64, and the spatial frequency of the run length in the binary image was calculated. Figure 2 shows the overall procedure. The run length histogram shows the distribution of the run

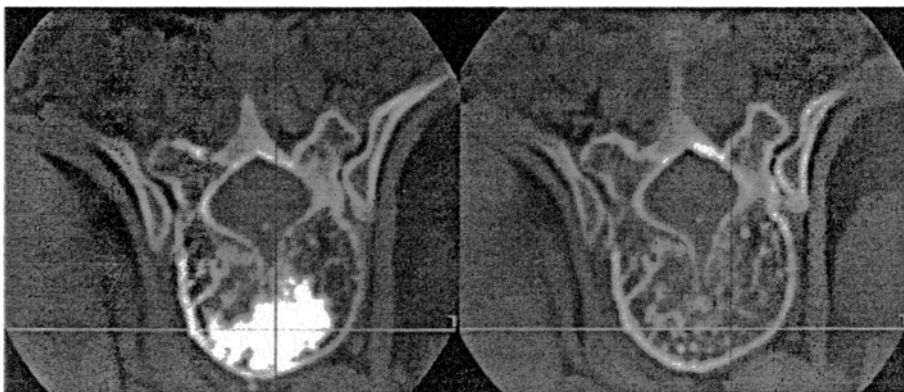

Fig. 1 CT images taken before (right) and after (left) percutaneous injection of PMMA. The radiopaque area in the left image indicates the region of bone cement injection

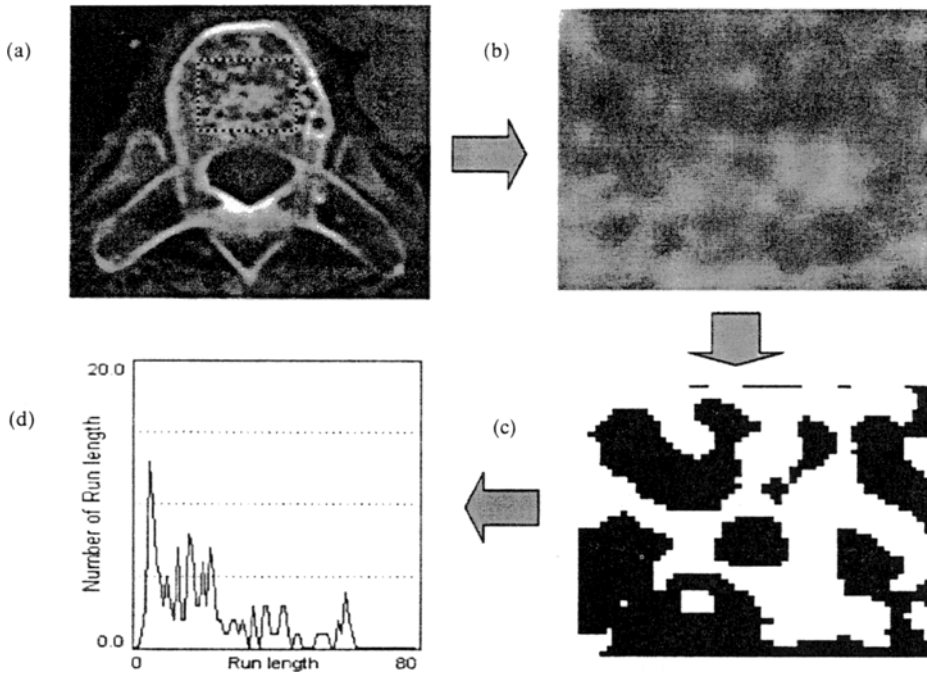


Fig. 2 Overall procedure of the gray level run length analysis suggested by Ito et al (Ito, 1995). (a) CT image shows an ROI (64×64) within the trabecular bone. (b) Selected ROI of the CT image. (c) Binary image of (b). (d) Run length histogram of the intertrabecular space

length in a binary image (Fig. 2(d)).

In this study, 3D visualization with semi-automatic segmentation was applied to postoperative CT images to estimate the volume of PMMA injection and to compare that with actually injected PMMA amount during vertebroplasty. The region growing segmentation technique is used to assign pixels in the CT images. For some cases, it can be difficult to distinguish the region of the trabecular bone from that of PMMA injected. In this study, several filtering and manual segmentation was applied to postoperative CT images in order to correct segmentation errors. This means that it is possible to correct the segmented results manually by human interaction. Surface rendering and volume rendering techniques were used for 3D visualization of the CT images. Figure 3 shows typical result of 3D visualization using volume rendering technique. Right image shows the volume rendered image of the region where bone cement was injected. Then the number of voxels of the segmented region was counted. The estimated volumes of PMMA injection based on

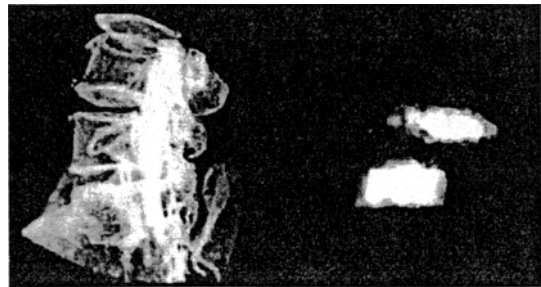


Fig. 3 Typical result of 3D visualization using volume rendering technique. Right image shows the volume rendered image of the region where bone cement was injected. PMMA volume can be calculated by a product of the number of the voxel and the volume (0.234 mm×0.234 mm×1 mm) of the voxel

3D visualization were calculated by multiplying the volume of the voxel (0.234mm×0.234mm×1mm).

The three-dimensional finite element model of a human lumbar vertebra (L1) was formulated using the geometric data acquired from 1mm thick computed tomography (CT) scans (trans-

verse slices). This model serves as a baseline model from which the patient and subsequent surgical models were constructed. ANSYS (Swanson Analysis Systems Inc., Houston, PA) that is a commercially available finite element program package is used. A total of 9585 three-dimensional isoparametric eight-nodal (brick) elements were used for construction of the intact model. The model includes the cortical bone, the trabecular bone, the both sides of the endplate of the vertebral body, and the posterior elements. The material properties chosen for the normal model were taken from the literatures (Grosland, 1998). (Table 2)

To validate this model, the axial displacement of the superior endplate was assessed and they were compared with the published experimental data under the same loading conditions (Brinckmann, 1983). In the osteoporotic patients, it is reported that the reduction of bone capacity occurs relatively more in the trabecular cancellous bone than in the cortical bone, endplates, and posterior elements (Suk, 1997). To simulate osteoporosis in each patient, his/her BMD data were converted into appropriate elastic moduli using the following equation reported by Lotz (Lotz, 1990).

$$E=0.5(QCT)^{1.2} \quad (R^2=0.90, p<0.001) \quad (1)$$

E: elastic moduli

QCT: the level of BMD by quantitative computed tomography measurement.

Table 2 The material properties assigned to various structures in the finite element model

Material	Elastic Modulus (MPa)	Poisson's Ratio (V)
Cortical beon	12000	0.3
Endplate	10000	0.3
Posterior element	3500	0.3
Normal trabecular bone	140	0.2
Osteoporotic trabecular bone	8.9,18.6, 30.5, 53.4*	0.2
Bone cement (PMMA)	2200	0.2

*: Based on the BMD level of the patient. The elastic modulus was calculated from BMD by suing the Eq. (1)

R²: coefficient of determination
 p: significant probability.

To reduce the number of patient models, four patients with different level of BMD were selected while the patients with similar levels of BMD were excluded as shown in Table 1. On each patient model, the vertebroplasty was simulated: The osteoporotic trabecular bone was replaced with PMMA according to the amount of injection. To evaluate biomechanical effects of PMMA volume on the structural integrity of the osteoporotic vertebra, each vertebroplasty model was simulated with PMMA volume percentage of 10%, 15%, 20%, 25%, and 30% with respect to the total trabecular volume. This is the range assessed from the image analysis of CT with 30% being the maximum (Table 1). Figures 4~5 illustrates a typical FE model with injected PMMA. Here, the location of PMMA volume within the vertebrae was approximated by examining their postoperative CT images.

Compressive loads of 1500N and 2500N were independently applied as a uniform pressure on the superior surface while the inferior endplate was fixed in all directions. Here, 1500N was the load on the vertebra when a person (70Kg) is standing with 20Kg of weights in hands (Nachemson, 1966). This load was chosen to simulate one of more difficult loading situations that a patient can face in a normal daily life. On the other hand, Tohmeh et al. have experimentally produced the compression fractures of the lumbar

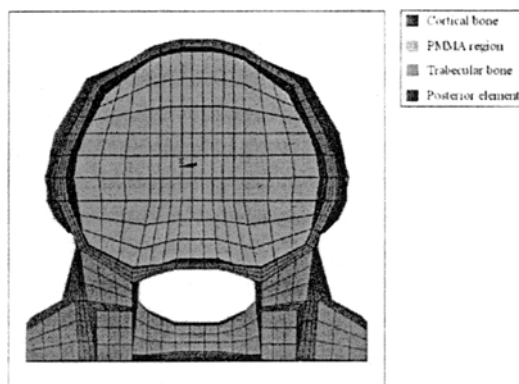


Fig. 4 A transverse plane view of the finite element model

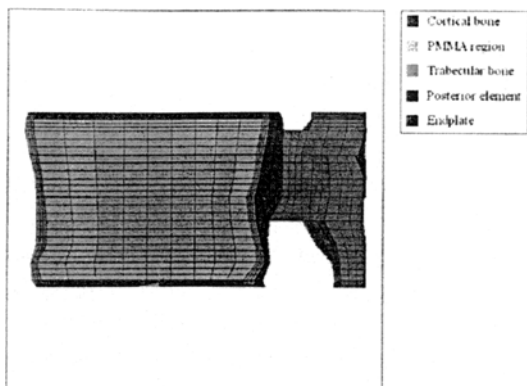


Fig. 5 A sagittal plane view of the finite element model

vertebra by subjecting the osteoporotic vertebral body to axial compression (Tohmeh, 1999). They reported the ultimate compressive strength of about 2400N at which the superior endplate underwent an axial displacement of about 2.3mm. Accordingly, the displacement of the superior endplate in our surgery models was assessed to investigate the structural integrity of each model with respect to the changes in BMD and the volume of PMMA injection. In addition, the risk of vertebral body fracture was predicted.

3. Results

Whereas two indices of the gray level run length analyses were calculated from preoperative CT images, PMMA volume using 3D visualization was calculated from postoperative CT images. Figures 6~7 shows the relationship between these parameters and actually injected PMMA volume during vertebroplasty. Results show that the calculated PMMA volume was slightly more than injected PMMA volume. The injected PMMA volume increased as the area of the intertrabecular space increased. It increased also with decreases in the area of trabecular bone. In order to do quantitative analysis, the correlation coefficient(r) between each parameter was calculated. Table 3 shows the correlation coefficient between injected PMMA volume during vertebroplasty, calculated PMMA volume using 3D visualization, and two indices of textural

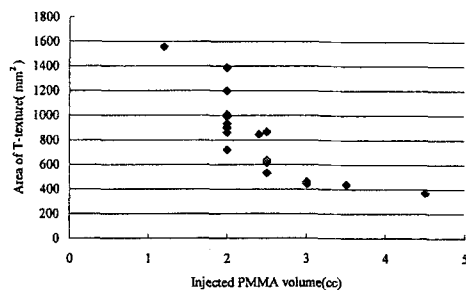


Fig. 6 Relationship between injected PMMA volume and the area of trabecular As injected PMMA volume increased, the area of the intertrabecular space increased

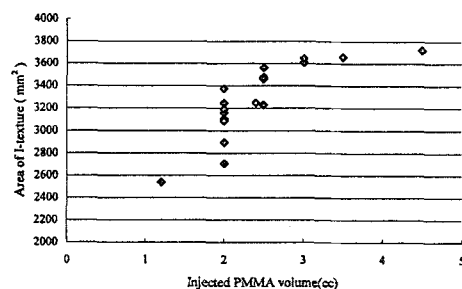


Fig. 7 Relationship between injected PMMA volume and the area of intertrabecular space As injected PMMA volume increased, the area of trabecular bone decreased

Table 3 Correlation coefficients between injected PMMA volume during vertebroplasty, calculated PMMA volume using 3D visualization of postoperative CT images and textural features of preoperative CT images

	Calculated PMMA volume	Area of Intertrabecular	Area of Trabecular
Injected PMMA volume	0.85	0.90	-0.90
Calculated PMMA volume	1	0.81	-0.81

features of CT images. The correlation coefficient between injected and calculated PMMA volume can be used as an index of how well the procedure of segmentation and 3D visualization were performed. The coefficient was 0.85, which showed relatively good agreement with each other. This




Fig. 8 Comparison of the calculated results with the previously published data by Brinckmann et al. (Brinckmann, 1983)

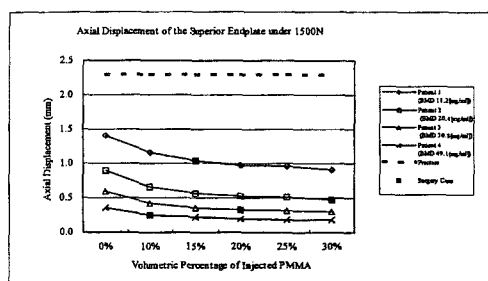


Fig. 9 Axial displacement of the superior endplate under 1500N with respect to percent PMMA volume. The actual injected amount of PMMA is indicated with a black square (■) for each patient. The displacement of 2.3mm at which the fracture would likely occur according to Tohmeh et al. (Tohmeh, 1999) is shown with a dotted line

means that reconstructed PMMA injected region was well defined. Table 3 shows that it strongly correlates with actually injected PMMA volume and the area of the intertrabecular spaces and the area of the trabecular calculated from the binary images ($r=0.90$ and $r=-0.90$, respectively). As expected, as the index for intertrabecular spaces showed positive correlation, the index for trabecular indicated negative correlation.

Figure 8 shows the result of validation of axial displacement for the baseline model. Our FE results were in close agreement with those reported by Brinckmann et al (Brinckmann, 1983). This validated the fact that the mechanical behavior of our baseline model follows the actual specimen.

Our FE results are shown in Figs. 9-10 for the axial compressive loads of 1500N and 2500N,

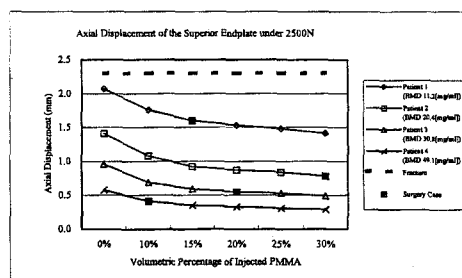


Fig. 10 Axial displacement of the superior endplate of the vertebra due to percent PMMA volume under 2500N. The actual injected amount of PMMA is indicated with a black square (■) for each patient. The displacement (2.3mm) at which the fracture would likely occur according to Tohmeh et al. (Tohmeh, 1999) is shown with a dotted line

respectively. Although, no immediate risk of vertebral body fracture was indicated regardless of changes in applied load, BMD of patients, or percent PMMA volume, it can be seen that the fracture risk has significantly diminished due to PMMA augmentation as compared to 0% PMMA volume (i. e., before vertebroplasty). In fact, the axial displacement in Patient 1 decreased to 1.41mm with 30% volume of PMMA injection from 2.07mm before vertebroplasty (Fig. 10). Also, the axial displacement at 30% volume in Patient 4 (BMD, 49.1 mg/ml) were the same the corresponding value of a normal vertebra (0.29mm) listed in Fig. 8. This suggests that it is very important to determine the maximum allowable volume for each patient preoperatively to restore the structural integrity as the patients with higher BMD (i. e., less severe osteoporosis) were far less likely to experience the fracture as opposed to the ones with higher value as evidenced by lower values of the axial displacement. In addition, the higher the compressive load, the more deformation the endplate was to undergo (Fig. 9 vs Fig. 10).

The effectiveness in achieving the structural reinforcement due to different volumes of PMMA is illustrated in Fig. 11 for 2500N of compressive load. The percentage in the vertical axis is obtained as the changes in axial displacement due to a given % volume of PMMA with respect to the

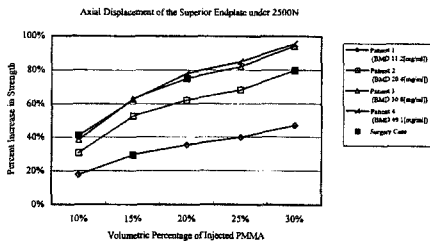


Fig. 11 Percent increase in structural integrity due to injection of PMMA. All data are relative to 0% injection under the axial compressive load of 2500N. The actual amount of PMMA volume is indicated with a black square (■) for each patient

predicted preoperative cases. (i. e., 0% PMMA injection) For example, about 30% increase in structural integrity of the vertebra can be found with 15% of PMMA injection compared to 0% in Patient 1. Also it can be postulated that the vertebra of Patient 4 (BMD, 49.1 mg/ml) could have experienced close to 100% increase in strength if PMMA volume was 30% instead of the actually injected volume of 15% at which only 40% increase was noted. The slopes of the curves in Fig. 11 all showed a decreasing trend, which suggest diminishing effectiveness with successive increase in PMMA volume. Results showed that at least 50% increase in vertebral strength could be expected for any given patients with the maximum allowable 30% volume injection. However, a closer look revealed that for Patient 4 additional 10% increase in PMMA (from 20% to 30%) resulted increase in strength only by 10%. On the other hand, additional 60% increase in strength could have been obtained if 30% volume was injected instead of the actual volume of 10% in Patient 1. This again shows it is necessary to find the optimum amount of PMMA before the surgery.

4. Discussion and Conclusions

Vertebroplasty is one of the newest surgical approaches for the treatment of the osteoporotic spine. Clinical studies have shown that control of PMMA volume is one of the most critical factors in preventing complications. Although much effort have been made to elucidate its biome-

chanical efficacy, few studies have demonstrated the relationship between the BMD levels and amount of PMMA required to sustain various loads for a given patient in daily life. Development in medical imaging and finite element analysis techniques in orthopedic biomechanics has made the authors realize that more realistic and clinically relevant finite element models can be constructed with more closer attention to the patient's morphologic data and bone mineral density data based on CT images. To do so, the followings were hypothesized: 1) a relationship could be drawn between the amount of PMMA volume injection and textural features of the trabecular bone in preoperative CT images, 2) the amount of PMMA volume injection could be estimated based on 3D reconstruction of postoperative CT images, and 3) the degree of structural reinforcement in the osteoporotic vertebrae could be related to the amount of PMMA injection and the level of BMD.

In this study, we examined whether a correlation exists between injected PMMA volume and textural features of patient's CT image and found that strong correlation between injected PMMA volume and the area of the intertrabecular space, and the area of trabecular calculated from the binary images of preoperative CT images. Consequently, we were able to demonstrate that proper amount of PMMA volume injection could be predicted based on the results from this study and could be used for better clinical outcome in vertebroplasty.

The dimensions of our FE models were constructed based on that of the first lumbar vertebra (L1) from a normal person without any symptoms of disease. The morphologic variations between the patients were disregarded. Instead, the material properties of each patient were taken into consideration by converting BMD data to the appropriate elastic moduli by using the Eq. (1). Depending on the amount of PMMA injection, the cancellous bone volume was substituted with that of PMMA depending on the volumetric percent data of PMMA of each individual patient so that effectiveness of PMMA injection could be delineated more uniformly with respect to differ-

ent levels of BMD in patients. In addition, the variation in the level of the vertebra at which the actual vertebroplasty was performed was simplified as L1. This was possible because it has been reported that the biomechanical characteristics do not vary much whether it is thoracic or lumbar vertebrae, or whether it is L1 or L4 (Tohmeh, 1999). The same goes for using the percent volume instead of the amount of volume since there are great variations in the volume of vertebra among the patient groups. It was intended to restrict the number of the variables as much as possible in this study. Only the BMD and the percent volume of PMMA were the variables of importance here.

In majority of the osteoporotic patients who undergoes vertebroplasty the compression type fractures is expected if left untreated. Most of the height loss occurs in the middle of the vertebral body in compression fracture cases whereas the anterior part of the cortical body collapses in the wedge-type fractures. In our study, the axial displacement of the superior endplate was chosen to better quantify the loss of the vertebral height due to compressive loading. In fact, Tohmeh et al. (Tohmeh, 1999) in their in vitro experiment of the vertebrae with osteoporosis reported 2.3mm of maximum axial deformation at the top of the vertebral body where the superior endplate is located. At this point, the failure load was about 2400N of axial compression, which we used as our loading condition for our FE models. No cases in our FE analysis showed the axial displacement greater than 2.3mm. This suggests that there is no imminent risk of fracture under static loading condition. Among patients, the ones with lower BMD and the ones with less PMMA injection were more likely experience some types of axial deformation that might progress to eventual fracture. Since the loading condition in this study was simplified as static compressive loading only, we have to admit that it is far from realistic. In daily life, a person is subjected to cyclic loading of various types. Prediction of endurance limit of vertebrae under fatigue loading condition would be able to bring a better understanding of the long-term efficacy of the procedure itself.

Our FE results were able to demonstrate the PMMA injection had effectively reinforced the osteoporotic vertebrae in all patients. About 100% increase in vertebral strength (Fig. 11) and axial displacements close to that of a normal person (Fig. 10) were noted from the patients with relatively higher BMD (Patients 3 and 4). Even for the patients with very severe osteoporosis (Patient 1, BMD; 11.2 mg/ml), the axial displacement before surgery would have been over 2.0mm that is very close to the level of fracture (2.3mm). In this case, the actual injection of PMMA (15%) has increased the strength of the vertebral body by almost 30% (Fig. 11). Our results were able to suggest 50% increase if this patient had been injected to volumetric percentage of 30% instead.

The effectiveness that can be achieved through additional injection of PMMA showed a decreasing trend regardless of BMD level (Fig. 9). This suggests excessive amount of PMMA injection should be avoided as much as possible after the adequate level of strength is reached. Thermal damage to surrounding bone due to polymerization of PMMA, inability to remodel and integrate with bone, and toxicity of released monomers are some of the reported disadvantages of PMMA. Therefore the optimal level of PMMA injection should be more closely studied. Our image analysis showed the maximum allowable amount PMMA were 30% for the patients recruited for this study. The maximum BMD was 49.1ml/mg (Patient 4) and the axial displacement at PMMA volume of 30% reached the level of a normal person. It can be assumed that for the patient with BMD higher than 50mg/ml 30% volume of PMMA would be more than adequate. For future studies, it is needed to include a group of patients with higher BMD to get more comprehensive results.

In conclusion, we were able to demonstrate the efficacy of the vertebroplasty and predict the optimum volume of PMMA for a given patient based on the following findings:

- (1) We were able predict the PMMA volume for a given patient based on CT scan data using image analysis as well as the maximum allowable volume percent.

(2) The predicted volume was close to the actual volume of PMMA injection based on image analysis of postoperative CT images.

(3) Biomechanical analysis demonstrated the vertebroplasty was able to induce the structural reinforcement for osteoporotic vertebra regardless of BMD or percent volume of PMMA.

(4) Effectiveness of additional PMMA injection tended to decrease. Therefore, for patients with BMD well lower than 50mg/ml, injection of PMMA up to 30% volume of the vertebral body is recommended if situation permits. However, less than 30% is recommended otherwise to avoid any side effects from excessive PMMA because the strength of the vertebra has already reached that of a normal.

Acknowledgment

This study was supported by a grant (HMP-98-G-1-010) of the HAN (Highly Advanced National) Project, Ministry of Health & Welfare, R. O. K.

References

- Barr J. D., Barr M. S., Lemley T. J., and McCann R. M., 2000, "Percutaneous Vertebroplasty for Pain Relief and Spinal Stabilization," *Spine*, 25, No. 8, pp. 923~928.
- Brinckmann P, Frobin W, Hireholzer E, et al., 1983, "Deformation of the Vertebral End-Plate Under Axial Loading of the Spine," *Spine*, 8, No. 8, pp 851~856.
- Deramond H., Depriester C., Galibert P., and Gars D., 1998, "Percutaneous Vertebroplasty with Polymethylmethacrylate Technique, Indications and Results," *Radiol. Clinics of N. America*, 36, No. 3, pp. 533~546.
- Deramond H., Wright N., and Belkoff S. M., 1999, "Temperature Elevation Caused by Bone Cement Polymerization During Vertebroplasty," *Bone*, 25, No. 2, Supplement, pp. 17S~21S.
- Grosland N, 1998, "Spinal Adaptations in Response to Interbody Fusion Systems: A Theoretical Investigation. Ph. D. Thesis," Graduate College The University of Iowa, Iowa City Iowa, pp. 33~41.
- Ito M., Ohki M., Hayashi K., Yamada M., Uetani M., and Nakamura T., 1995, "Trabecular Texture Analysis of CT Images in the Relationship with Spinal Fracture," *Radiology*, 194, pp. 55~59.
- Lotz J., Gerhart T., and Hayes W, 1990, "Mechanical Properties of Trabecular Bone from the Proximal Femur: A Quantitative CT Study," *J Comput Assist Tomogr.*, 14, No. 1, pp 107~114.
- Martin J. B., Jean B., Ruiz D. S., Piotin M., Murphy K., Rufenacht B., Muster M., and Rufenacht D. A., 1999, "Vertebroplasty: clinical experience and follow-up results," *Bone*, 25, No. 2, Supplement, pp. 11S~15S.
- Mir A. H., Hanmandlu M., and Tandon S. N., 1995, "Texture Analysis of CT Images," *IEEE Eng. in Med. & Biol.*, pp. 781~786.
- Nachemson A., 1966, "The Load on Lumbar Discs in Different Positions of the Body," *Clin. Orthop.*, 45:107.
- Sternberg S. R., 1983, "Biomedical Image Processing," *IEEE Computer*, pp. 22~34.
- Suk S. I., 1997, *Spinal Surgery*, Choishineuihaksa, Seoul, Korea.
- Tohmeh A. G., Mathis J. M., Fenton D. C., Levine A. M., and Belkoff S. M., 1999, "Biomechanical Efficacy of Unipedicular Versus Bipedicular Vertebroplasty for the Management of Osteoporotic Compression Fractures," *Spine*, 24, No. 17, pp. 1772~1776.